

Hypospadias Surgery

by **Professor Ahmed T Hadidi**

*Professor of Paediatric Surgery, Heidelberg/Mannheim University, Germany
Professor of Paediatric and Plastic Surgery, Cairo University, Egypt*

Hypospadias surgery has developed into a well defined art and science. Surgeons dealing with this anomaly should have a detailed understanding of the various basic surgical principles and experience with delicate, precise optically assisted techniques and maintain a clinical workload that is sufficient to obtain consistently good results.

Incidence

One in 300 boys has hypospadias. In the United States a study reported that hypospadias was the most common congenital anomaly among whites. The incidence has been rising during the 1970s and 1980s.

Classification

Anatomic classification of hypospadias recognizes the level of the meatus without taking into account curvature. A more recent classification was described. This classification indicates the site of urethral meatus (before and after chordee correction), the prepuce (incomplete or complete), the glans (cleft, incomplete cleft or flat), the width of urethral plate, the degree of penile rotation if present and the presence of scrotal transposition (Fig. 1, 2). Using the general classification (Fig. 4), surgeons are able to conduct multi-centre studies to evaluate different techniques of repair.

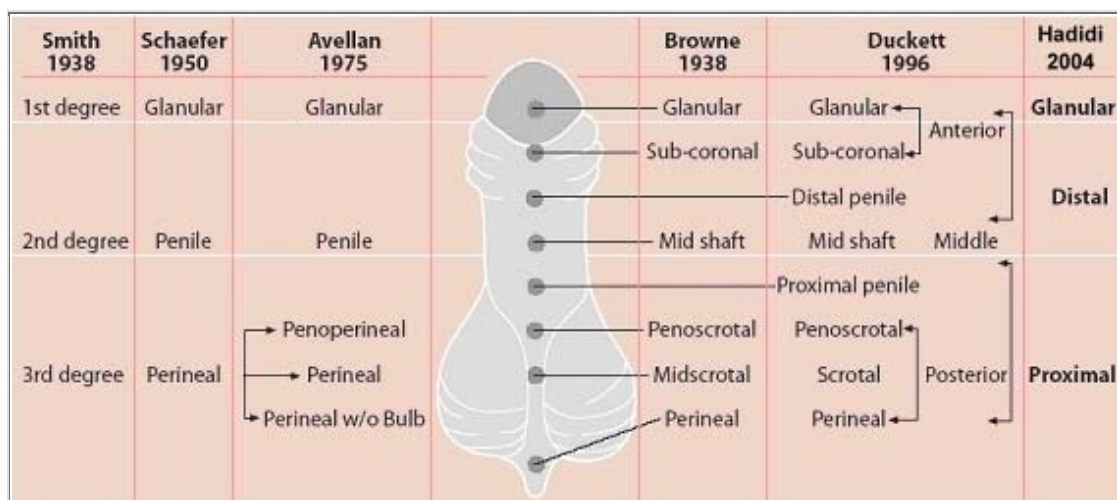


Fig. 1: Different classifications of hypospadias, according to location of meatus (modified from Sheldon and Duckett 1987).

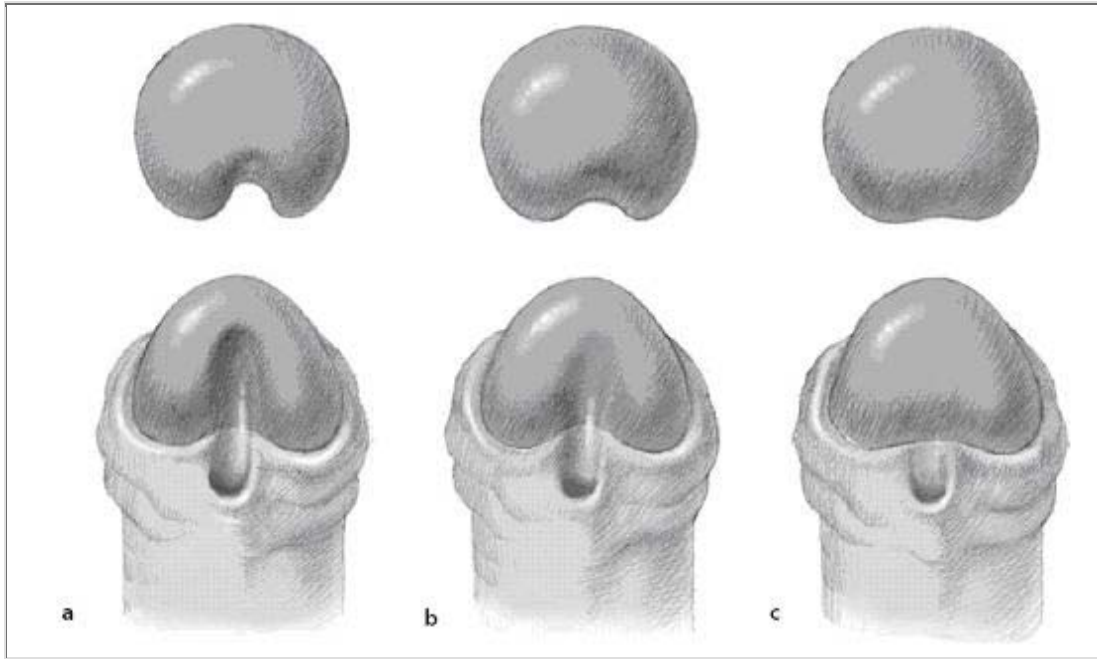


Fig. 2 a - c: Classification of glans configuration in hypospadias. (a) *Cleft glans*. There is a deep groove in the middle of the glans with proper clefting; the urethral plate is narrow and projects to the tip of the glans. (b) *Incomplete cleft glans*. There is a variable degree of glans split, a shallow glanular groove and a variable degree of urethral plate projection. (c) *Flat glans*. The urethral plate ends short of the glans penis, no glanular groove. There may be a variable degree of chordee, especially in proximal forms of hypospadias.

Timing of Surgery

Recent studies showed that the ideal time for hypospadias correction is between 3 and 15 months as the penis grows less than 1 cm during the first 3 - 4 years (Fig. 3).

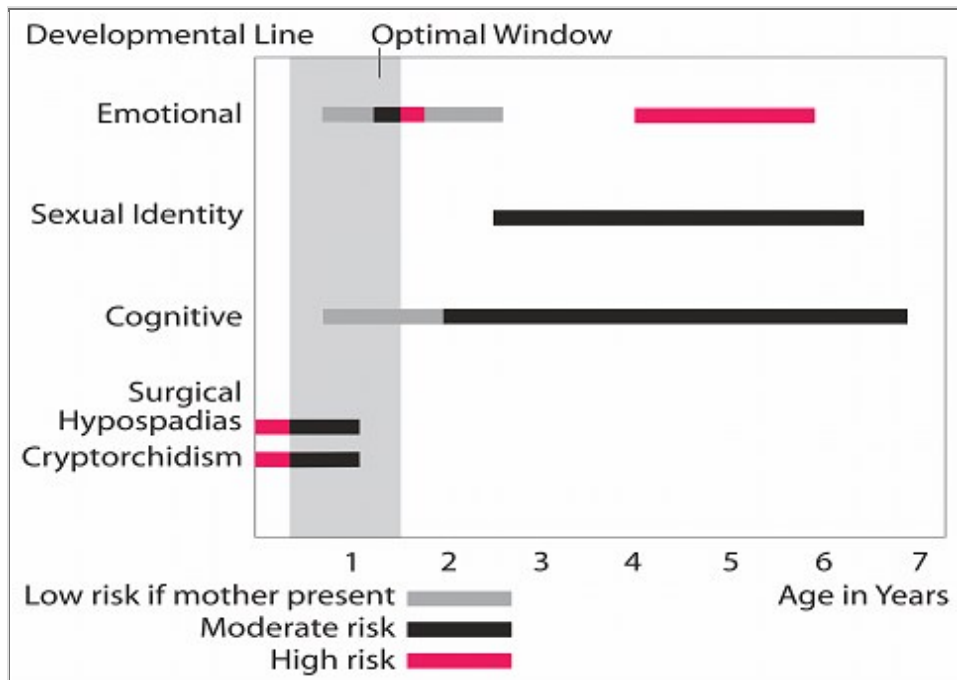





Fig. 3: Evaluation of risk for hypospadias repair from birth to age 7 years. The optimal window is from 3 to 15 months of age (modified from Schulz et al. 1983).

Name of the patient:




Date of birth:

Relevant personal details:



1. Site of urethral meatus (before chordee correction)

Glanular Hypospadias  Distal Penile Hypospadias  Proximal Hypospadias 




2. Site of urethral meatus (after chordee correction)

Glanular Hypospadias  Distal Penile Hypospadias  Proximal Hypospadias 




3. Prepuce

Complete  Incomplete 



4. Glans

Cleft  Incomplete cleft  Flat 



5. Chordee

No chordee  Superficial chordee  Deep chordee 

6. Urethral plate width

<1cm  ≥1cm 

7. Penile torsion

No torsion  Present 

8. Scrotal transposition



No transposition  Present 

Fig. 4: General classification: surgeons are able to conduct multi-centre studies to evaluate different techniques of repair

Different tissues used for correction of hypospadias

Although the penile repairs can be grouped into 8 major principles, depending on the tissues used, each has been subject to countless variations as one surgeon after another adds yet another modification to an already thrice-modified variation of a procedure adapted from a principle derived from the original.

To correct hypospadias and achieve a terminal meatus, one may use one of the following basic principles or tissues: 1) mobilisation of the urethra; 2) skin distal to the meatus; 3) skin proximal to the meatus; 4) preputial skin; 5) combined prepuce and skin proximal the meatus; 6) scrotal skin; 7) dorsal penile skin; 8) different grafts.

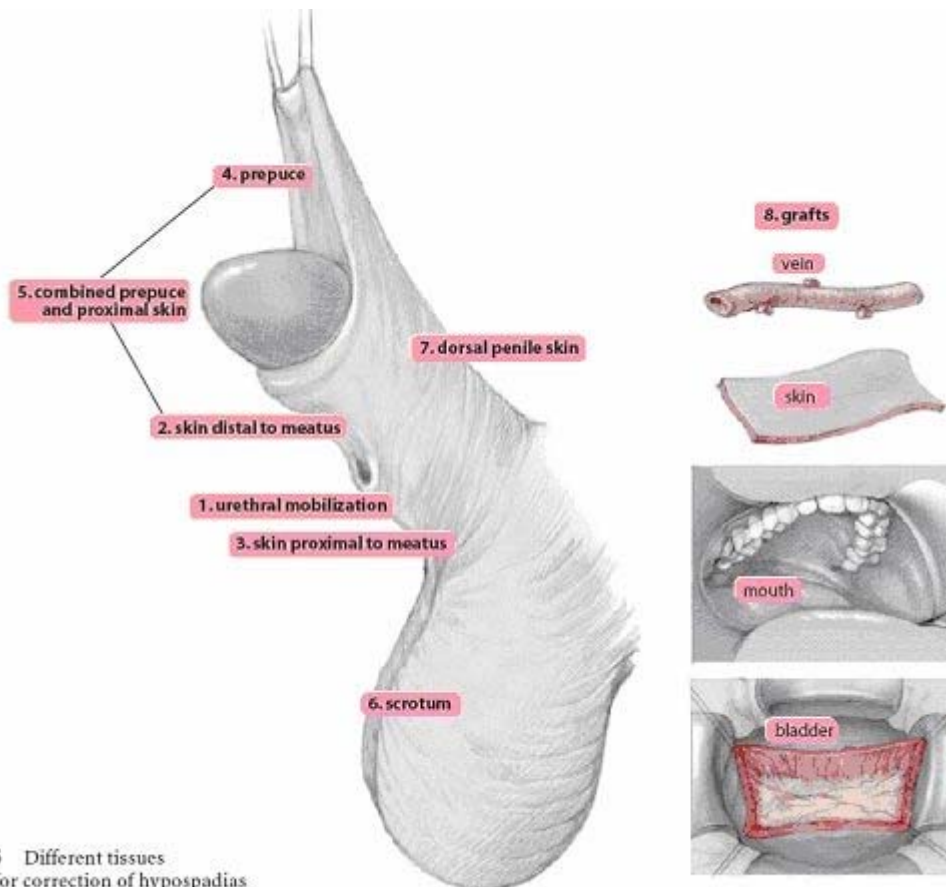


Fig. 5 Different tissues used for correction of hypospadias

1) Urethral mobilisation

- a) Urethral mobilisation first described by Beck and Hacker (1897).
- b) MAGPI described by Duckett (1981, midline vertical incision closed transversely and mobilization.
- c) M configuration by Arap (1984), a modification of MAGPI by placing two sutures on the ventral edge.
- d) UGPI modification of MAGPI by Harrison and Grobelaar (1997) by having a V-shaped incision around the original meatus, and having deep glanular wings before urethral advancement and upward rotation upward rotation of the glanular wings.

2) Skin distal to the meatus

A) Use of ventral skin distal to the meatus to reconstruct a completely epithelialized neo-urethra

- a) U-shaped incision as first described by Thiersch (1869). Notice the U incision is not central to avoid suture lines on top of each other.
- b) Pyramid repair by Duckett and Keating (1989) for Megameatus Intact prepuce (MIP).
- c) glanular hypospadias with cleft glans.
- d) DUG repair by Stock and Hanna (1997) combining U-shaped incision with vertical midline incision closed transversely.

B) Use of ventral skin distal to the meatus to reconstruct a partially epithelialized neo-urethra (Fig. 6)

- a) Duplay incomplete urethroplasty (1880)
- b) Denis Browne technique (1949)
- c) Rich et al (1989) hinging of the urethral plate
- d) Snodgrass Tubularized Incised Plate (TIP) urethroplasty (1994)

3) Skin proximal to the meatus

- a) Wood (1875) described meatal based flap with button hole of prepuce
- b) Omberdanne (1911) repair, a large round flap, and a purse string suture
- c) Mathieu repair (1932), a U-shaped incision and two suture lines
- d) Mustarde repair (1965), a rectangular flap and one suture line
- e) Barcat balanic groove technique (1969), and a deep midline incision
- f) Hadidi (1996) Y-V glanuloplasty modified Mathieu. A "Y-incision" in the glans, the center at the tip of glans, closed as a "V" and "dog-ears" opened. A small "V" is excised from the distal end of the flap.

4) Preputial skin

- a) Button holing of the prepuce described by Thiersch (1869).
- b) Midline incision of the prepuce described by Edmunds (1913) and Byars (1955).
- c) Preputial skin as a skin graft to cover the ventral defect of the penis described by Nove-Josserand (1897) and Bracka (1995).
- d) Preputial skin as a free skin graft to form the neo-urethra described by Devine and Horton (1961).
- e) Preputial Island Flap as described by Hook (1896), ... and Duckett (1980).
- f) Onlay Island Flap as described by Elder (1987).
- g) Preputial vascular fascia as a second protective layer described by Retik (1988).

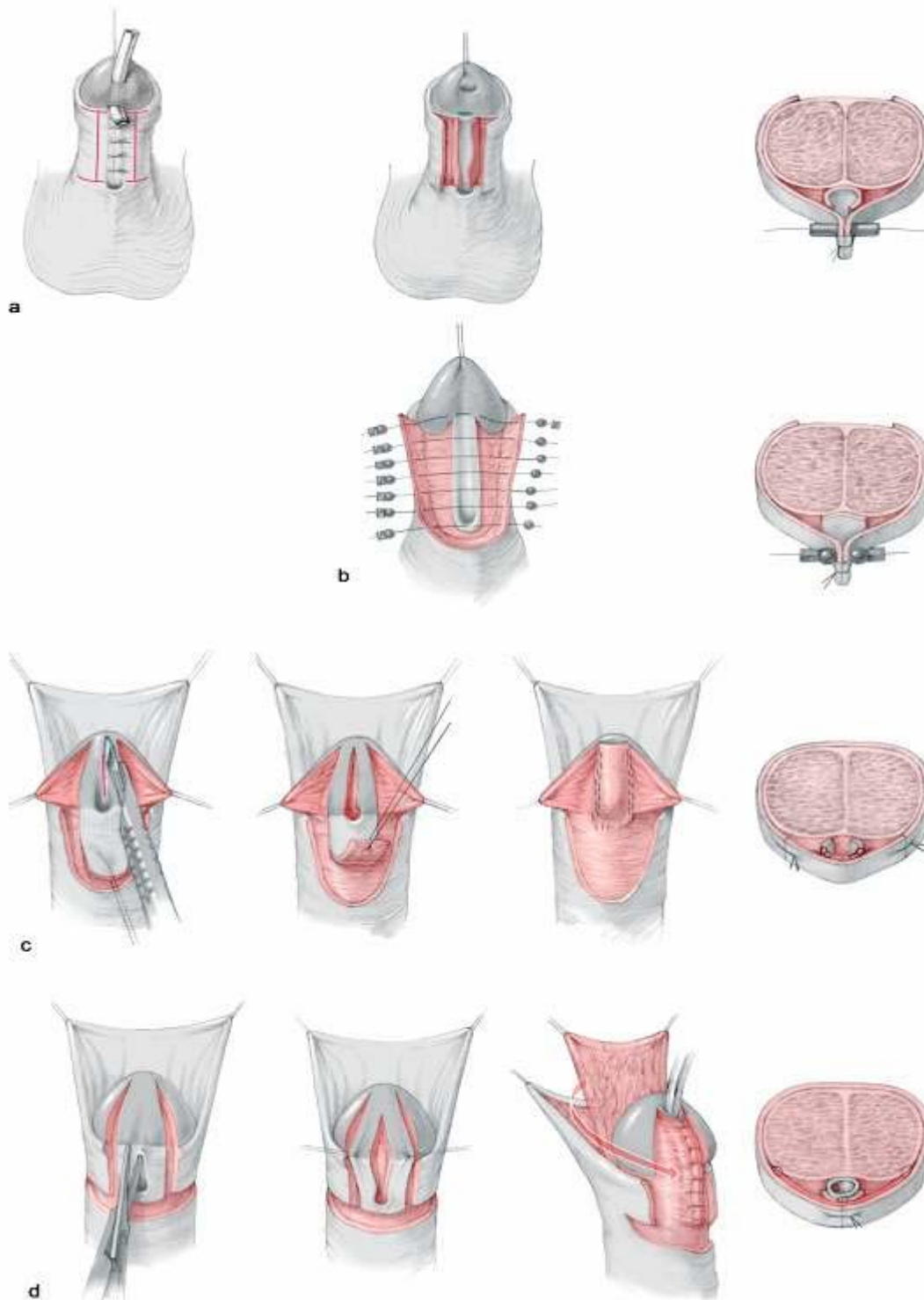


Fig. 6 a - d: Use of ventral skin distal to the meatus to reconstruct a partially epithelialised neourethra: (a) Duplay incomplete urethroplasty (1880); (b) Denis Browne technique (1949); (c) hinging of the urethral plate (Rich et al. 1989); (d) Snodgrass TIP urethroplasty (1994).

General principles

The ideal time for surgery is between 3 and 18 months. The infants are amnesic of the procedure and 70 - 80 % of anomalies can be managed on an outpatient basis.

Fine plastic, micro vascular or ophthalmic instruments including sharp serrated scissors are necessary. Optic magnification is helpful, although low magnification will suffice (X 1-2); some use an operating microscope routinely. Sutures like 6/0 or 7/0 Vicryl (polyglactin 910), Monocryl (poliglecaprone 25) or PDS (polydiacxonone) are used for urethroplasty.

To obtain a bloodless field, a tourniquet (released every 30 - 45 min) or Epinephrine (1:100 000) in 1 % lidocaine is used. Haemostasis should be ensured using bipolar diathermy. Urethroplasty should be performed around a 10 Fr catheter to avoid subsequent stenosis. A compressing dressing is applied post-operatively for 6 hours for hemostasis. The author prefers to remove the dressing after 6 hours but many surgeons prefer to use silastic foam or Tegaderm dressing for 2 - 5 days. The author does not leave a catheter inside the urethra routinely because it causes irritation and interferes with healing. However many surgeons leave a 6 Fr silastic catheter for 7 - 10 days.

Choice of operative technique

More than three hundred operations have been described for the treatment of hypospadias. Surgeons have proceeded through Browne repairs and scrotal flaps, to Duplay tubes, to free skin grafts, to island flaps and onlays, to bladder and buccal mucosal repairs, to a host of single-stage innovations, to different concepts of chordee correction and with all manner of bladder drainage systems. However, hypospadias repairs can be grouped into five or six major principles, depending on the tissues used.

For glanular hypospadias with mobile meatus, the author prefers to use the Inverted Y technique. For distal hypospadias, he prefers to use the Y-V glanuloplasty modified Mathieu approach. The author has adopted the lateral-based flap for proximal hypospadias. Two-stage repair may be preferred in patients with perineal hypospadias to avoid the use of hair-bearing areas of skin. Fig. 7 summarises the author's recommendations for primary hypospadias repair.

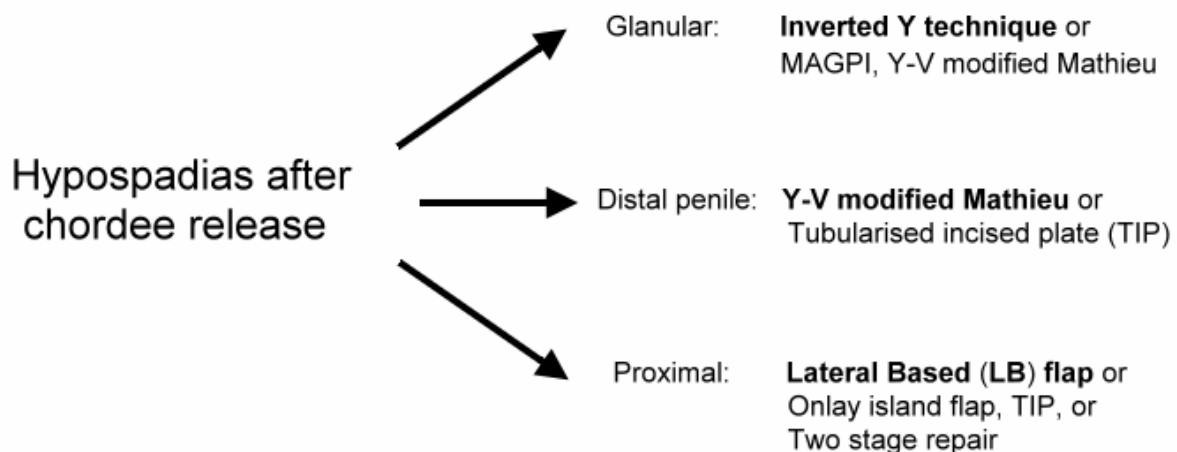


Fig. 7: Recommendations for primary hypospadias repair

The Y-V modified Mathieu procedure

The meatal-based flap technique of Mathieu is the most popular technique for distal hypospadias repair and has withstood the test of time. However, the major drawback of the original Mathieu technique is the final appearance of the meatus (a smiling meatus that is not very terminal). The Y-V glanuloplasty helps to employ the Mathieu operation in all forms of distal hypospadias and gives a terminal, slit like meatus. This will include about 70 to 80 % of patients with hypospadias. The only contraindication is the presence of severe chordee distal to the hypospadiac meatus.

Steps of Y-V glanuloplasty modified Mathieu technique: a) Y Incision; b) The three flaps elevated and coring to make a space for the neo-urethra; c) Y sutured as V with preservation of dog-ears; d) The dog-ears opened; e) U shaped flap; f) urethroplasty; g) A small dog-ear is excised near the meatus; h) A small V is excised from the neourethra; i, j) Meatoplasty and glanuloplasty (from Hadidi A; Y-V modified Mathieu in Hadidi A and Azmy A (eds.) Hypospadias Surgery, Art and Science. Heidelberg, Springer Verlag, 2004).

A Y-shaped incision is outlined on the glans with the centre of the Y where the tip of the neo-meatus will be located. Each limb of the Y is 0.5 cm long (Fig. 8 a). The Y-shaped incision is made deep and the three flaps are elevated and a core of soft tissue is excised from the bed of each flap to create a space for the neo-urethra (Fig. 8 b). The Y-shaped gap is sutured as a V making sure to keep the dog-ears at the upper ends of V suture lines (Fig. 8 c). These dog-ears will enlarge the circumference of the tip of glanular wings 1 cm at least (Fig. 8 d).

A U-shaped incision is made slightly longer than the distance between the meatus and the designed tip of the neo-meatus. The longitudinal incisions should diverge away from the hypospadiac meatus to allow for adequate blood supply to the flap. The U-shaped incision will open wide the dog-ears (Fig. 8 e).

A continuous subcuticular running Vicryl® 6-0 on a *cutting* needle is used for neo-urethra reconstruction. The subcuticular suture is continued until the tip of the glans, then goes back with the same stitch in a running stitch approximating the flap fascia to the depth of the glans and the shaft of the penis (*double breasting*). Thus, one will have one knot only for the whole two layers (Fig. 8 f).

A small V is excised from the apex of the parametatal flap and the meatus is reconstructed (Fig. 8 g).

The glanular wings are approximated using *transverse mattress interrupted sutures* (Fig 8 h).

The preputial skin is left intact. The prepuce may be reconstructed if parents desire after 6 months when everything has healed well or circumcision performed. Usually, it is not recommended to perform circumcision during urethroplasty, in case complications occur and the preputial skin becomes important.

Complications

Fistula occurs in 2 - 5 % of patients

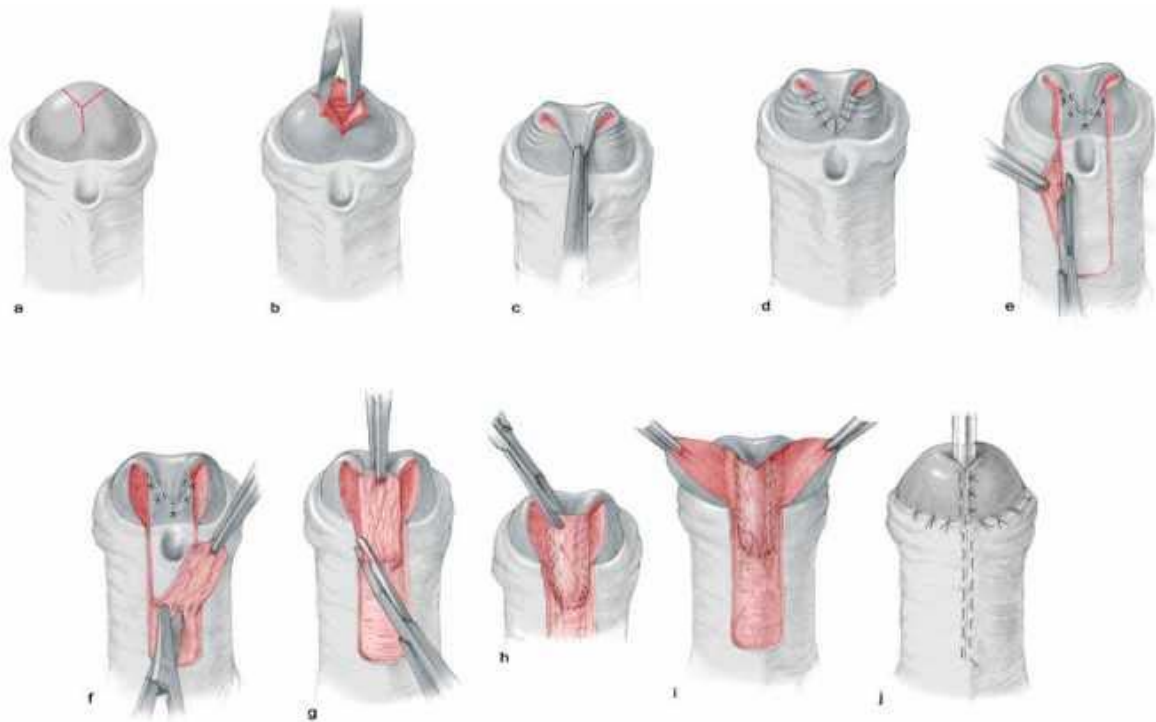


Fig. 8 a - j: Steps of Y-V glanuloplasty modified Mathieu technique. (a) Y incision. (b) Elevation of the three flaps and coring to make a space for the neourethra. (c, d) Y sutured as V with preservation of dog-ears. (e) U-shaped flap. (f) The flap is elevated, taking care to preserve its fascia. (g) The dog-ear is excised from both lateral ends of the flap. (h) Urethroplasty is performed in two layers. (i) A V is excised from the tip of the flap. (j) Meatoplasty and glanuloplasty.

Lateral Based (LB) Flap

The lateral based flap may be used in all types of proximal hypospadias. This flap with double blood supply, combines the advantages of meatal-based flap, and preputial pedicle flap techniques into one procedure without the need for an intervening anastomosis. It also allows for extensive excision of ventral chordee and the urethral plate (if necessary) without damaging the flap.

Operative steps

A deep Y-shaped incision is made on the glans. The centre of the Y is where the tip of the neo-meatus will be located. The upper two short limbs of the Y are 0.5 cm long. The long vertical limb Y extends down the whole length of the glans penis to the coronary sulcus (Fig. 9 a). The resultant three flaps are elevated and a core of soft tissue is excised to create a space for the neo-urethra (Fig. 9 b).

Meticulous excision of any chordee or fibrous bands is carried out. This fibrous tissue is particularly heavy in the midline but may extend well laterally. The meatus is assessed and a cut back is made to widen the meatus (Fig. 9 c).

A rectangular skin strip is outlined extending proximally from the urethral meatus staying in the midline in the scrotum to avoid potentially hair bearing skin. The skin strip is extended distally and laterally by curving towards the prepuce. This allows for formation of a very long tube that can reach the tip of the glans wherever the original position of hypospadias meatus is (Fig. 9 d).

The skin incision is carried completely around the meatus leaving a small cuff of skin. The meatus is freed proximally. The adjacent penile skin is elevated (rather than the flap). The flap with its pedicle is mobilised through the dorsum of the penis and down to the root of the penis to avoid penile rotation. The skin strip and proximal cuff are tubularised around a Nelaton catheter size 10 Fr inside the urethra. The author prefers to use Vicryl 6/0 on a cutting needle. Suturing is carried out from distal to proximal in a subcuticular continuous manner. Several reinforcing interrupted stitches are usually taken to form water tight tube (Fig. 9 e).

The neomeatus is then constructed by suturing the terminal end of the neourethra to the central V of the glans. A final slit like meatus is obtained by excising a small V from the tip of the neo-urethra. Then, the glanular wings are wrapped around the neourethra and approximated in the midline. When completed a near normal wide meatus is created at the tip of a conical shaped glans. The long anastomotic contact between the neo-meatus and glans created by the Y glanuloplasty is important to create a wide meatus and avoid post operative meatal stenosis. The vascular areolar subcutaneous tissue layer is then used to provide a complete covering for the neourethra (Fig. 9 f). The skin is closed in the midline using 6/0 Vicryl in a continuous transverse mattress. This helps to simulate the normal ventral median skin raphae (Fig. 9 g). A percutaneous suprapubic cystocath is inserted into the bladder for 10 - 14 days. A compression dressing is applied for 6 hours for haemostasis.

Complications

Fistula occurs in 6 - 12 % of patients. Penile rotation may occur if the pedicle is not mobilized down to the root of the penis.

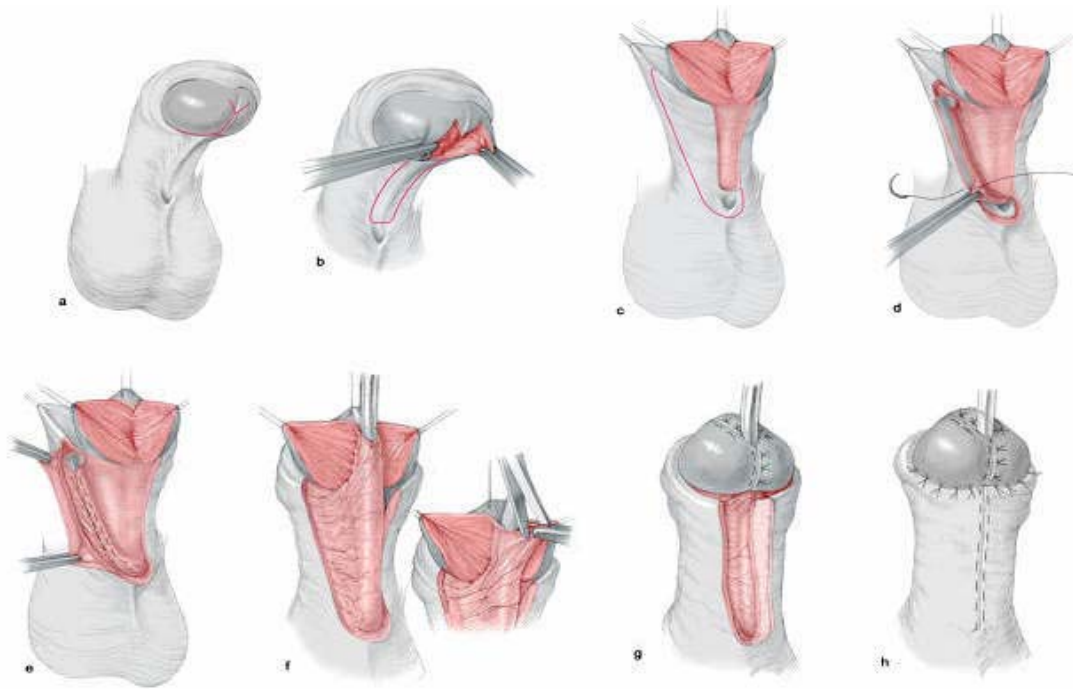


Fig. 9 a - h: Steps of lateral-based (LB) flap technique for single stage repair of proximal hypospadias. (a, b) Y-shaped deep incision of the glans; (c) chordectomy; (d) outline skin incision and flap mobilisation; (e) formation of the neourethra; (f) glanulomeatoplasty; (g) protective intermediate layer; (h) skin closure

Tubularized Incised Plate Urethroplasty (TIP)

The Tubularized Incised Plate repair (**Snodgrass 1994**) is based on the assumption that midline incision into the urethral plate may widen it sufficiently for urethroplasty without stricture. Many centres report excellent results with this technique. There are two important criteria to achieve good results: the urethral plate should not be less than 1 cm wide and there should be no distal deep chordee. The technique has gained popularity because it is easily performed, with few complications and results in a slit like meatus. The importance of regular dilatation is still controversial.

Operative steps

A traction suture is placed in the glans just beyond the anticipated dorsal lip of the neomeatus. A circumsccribing skin incision is made 1 to 2 mm proximal to the meatus and the shaft skin is degloved to the penoscrotal junction. If a portion of the native urethra is excessively thin, however, a "U" shaped incision is made extending to more healthy tissues.

The urethral plate is separated from the glans wings by parallel incisions along their junction. A tourniquet placed at the base of the penis provides better visualization of the operative field. The glans wings are mobilized avoiding damage to the margins of the urethral plate.

A relaxing incision is made using scissors in the midline from within the meatus to the end of the plate. The incision should not reach the tip of glans. The depth of the relaxing incision depends on the plate width and depth. A 6 Fr stent is secured into the bladder. A 7-0 polyglactin is preferred to tubularize the urethra, with the first stitch placed at approximately the midglans. Tubularization is completed with a 2 layer running subepithelial closure.

Any adjacent dartos tissues are used to cover the neourethra and then a dartos pedicle is developed from the dorsal shaft skin, button-holed, and transposed to the ventrum to additionally cover the repair. The coronal margins of the glans are approximated with subepithelial 6 - 0 polyglactin. The skin edges of the glans are sutured, and the meatus with 7 - 0 ophthalmic chromic catgut.

Byars' flaps are created from the preputial skin to mimic the median raphe. Subepithelial stitches are used throughout to avoid suture tracks. A tegaderm dressing is applied. The stent is removed approximately 1 week later.

Complications

Fistula occurs in 2 - 15 % of patients. Meatal stenosis 5 - 20 %.

Transverse Preputial Island Flap

Operative steps

A deep Y-shaped incision is made on the glans as in the Lateral based (LB) flap technique. Meticulous excision of any chordee or fibrous bands is carried out. This fibrous tissue is particularly heavy in the midline but may extend well laterally. The meatus is assessed and a cut back is made to widen the meatus. A sub coronal incision is made around the glans. The incision continues laterally until it reaches the gap where the fibrous chordee was excised.

The penile and preputial skin is dissected free off the shaft from distal to proximal close to the Buck's fascia preserving the arteries that constitute the pedicle to the preputial flap.

A 1.5 cm wide rectangular flap is prepared. The length must suffice the gap between the meatus and the tip of the glans. Extra length can be obtained by going down into the penile skin in a horseshoe fashion on either side. The flap is tubularised around a 10 Fr catheter and sutured into the meatus beginning with the suture line underneath the pedicle utilizing interrupted 7-0 polyglactin suture.

Then, the pedicle is separated from the outer preputial skin in a plane just below the intrinsic blood supply of the outer prepuce down to the root of the penis.

The upper small median flap resulting from the Y incision is sutured to the upper dorsal end of the tube. A V is excised from the tip to obtain a slit like meatus. The mobilized glans wings are rotated medially around the neo-urethra. Three transverse mattress sutures maintain firm approximation of the glanular wings in the midline. The mobilized glans wings are rotated medially and three transverse mattress sutures maintain firm approximation of the glanular wings in the midline. De-epithelialisation of skin to protect the neourethra.

Complications

Fistula, wound disruption, diverticulum and rotation occur in 10 - 30 % of patients.

MAGPI (Meatal Advancement and Glanuloplasty Incorporated)

This technique may be used in glanular hypospadias with mobile urethral meatus that can be pushed to the tip of the glans. If the meatus is not mobile enough, the results are less satisfactory.

Meatal advancement: The dorsal lip distal to the meatus is cut longitudinally to avoid urine deflecting downwards. In the classic MAGPI, the incision is closed transversely (Heineke Mickulicz technique). Thus the dorsal meatal edge is advanced distally. Recently, some surgeons leave it without closure as a modification from Snodgrass technique.

The glanuloplasty is accomplished by elevating the ventral edge of the meatus forwards and rotating the flattened glanular wings upwards and ventrally in a conical manner. It is important to reapproximate glans tissue in a two layers fashion with a deep closure of glans mesenchyme and a superficial layer of glans epithelium. There have been several modifications of this technique (Duckett and Baskin, 1996).

Complications

Meatal regression may occur if the technique is used in patients with immobile urethral meatus. Precision is required to achieve a conical glans.

Onlay Island Flap

The Onlay Island Flap is ideal for patients with proximal hypospadias without deep Chordee.

According to the author experience, most patients with proximal hypospadias have deep chordee that necessitates excision. However, recently, many surgeons prefer to perform dorsal placcation if the chordee is less than 30o after skin degloving and preserve the urethral plate.

Operative steps

The tip of the neo-meatus is identified. This point is where the flat ventral surface of the glans begins to curve around the meatus. A midline vertical incision is made in the glans until the width of the glanular groove is adequate for the meatus. The vertical incision is left open without closure for secondary epithelialisation.

A subcoronal incision is made around the glans. The incision continues on either side of the urethral plate at the junction with the normal ventral skin, then up on either side of the glanular groove to the apex of the glansplasty.

The skin is degloved from distal to proximal close to the Buck's fascia preserving the arteries that constitute the pedicle to the preputial flap. The pedicle is then separated from the outer preputial skin in a plane just below the intrinsic blood supply of the outer prepuce. The elevation of the glans wings will permit them to be rotated around the urethroplasty.

A 1-cm wide onlay flap is prepared from the inner prepuce. The onlay flap is sutured into place beginning with the suture line underneath the pedicle utilizing running 7-0 polyglactin suture. The glans should be drawn together setting up the first stitch of the glansplasty ventrally at its apex. The mobilized glans wings are rotated medially around the neo-urethra. Three transverse mattress sutures maintain firm approximation of the glanular wings in the midline.

Complications

Fistula, wound disruption, rotation, recurrent curvature occurs in 10 - 20 % of patients.

Two Stage repair

A small group of patients with severe proximal hypospadias, chordee, and a small phallus as well as patients with recurrent hypospadias and fibrous unhealthy skin may benefit from a two-stage procedure (Fig. 10).

In the first stage, a circumferential incision is made proximal to the coronal sulcus, the chordee is excised, and the penile shaft is de-golged. Penile straightening and removal of all chordee tissue must be confirmed by the use of the artificial erection test.

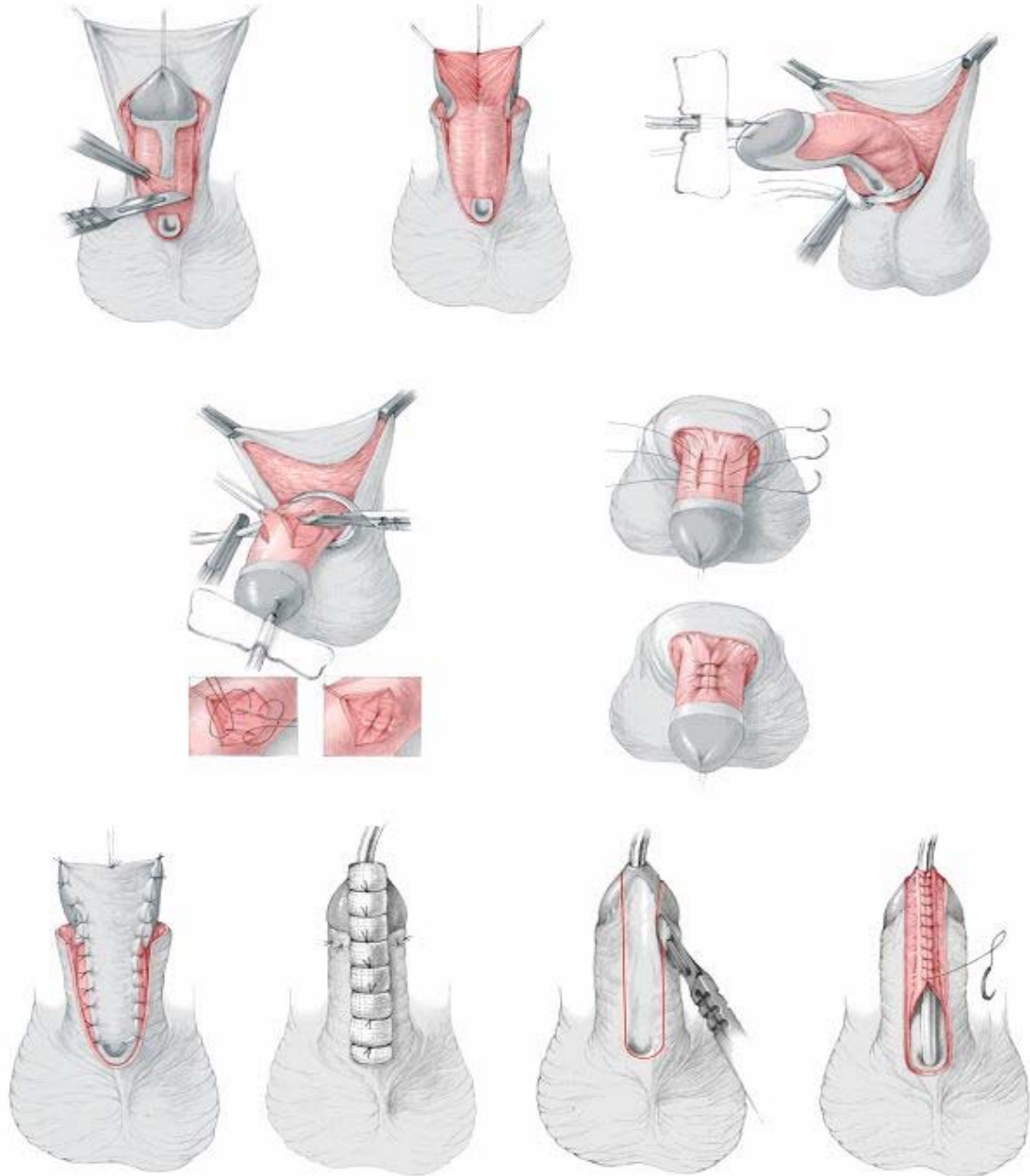


Fig. 10: Steps of two stage repair: identification of chordee, excision of ventral chordee and plication if needed. Coverage of raw surface with skin graft. Tubularisation as a final Stepp

The glans is divided deeply in the midline to the tip. The dorsal foreskin is unfolded carefully and divided in the midline. A midline closure is performed, and the midline sutures catch a small portion of Buck's fascia. The bladder is drained with an 8 French Silastic Foley catheter for approximately 5 to 7 days.

If there is inadequate genital skin available, buccal mucosa or rarely bladder mucosa may be used.

The buccal mucosa is harvested from the inner surface of the cheek or the inner surface of the upper or lower lip. The parotid duct is identified opposite the upper molars, and cannulated with 3-0 nylon. The graft is outlined and the submucosa infiltrated with 1% lignocaine containing 1:2000 epinephrine. The graft is incised and the mucosa is dissected away by sharp dissection.

The second stage of the procedure is carried out 6 to 12 months later. The previously transferred skin or mucosa is used to reconstruct the glans and urethra. A 16-mm diameter strip is measured, extending to the tip of the glans. The strip is tubularized with a running subcuticular stitch of 6-0 Vicryl® all the way to the tip of the glans. Tension is reduced by generous mobilization and undermining of adjacent tissues. A protective intermediate layer (either tunica vaginalis or dartos) helps to reduce post-operative complications.

The lateral skin edges are mobilized, and the remaining tissue is closed over the repair in at least two layers. A strip of skin (3 - 5 mm wide) is de-epithelialised on one side to provide a raw surface of deep dermis. This is achieved by cutting 2 or 3 fine longitudinal strips with a pair of small curved-on-scissors. The medial edge of the shaved flap is brought across the buried urethroplasty and sutured to fascial tissue beneath the other flap (double breasting).

Artificial erection test and chordee (curvature) correction

Ventral curvature (chordee) may be evaluated by the artificial erection test. There are two types of chordee associated with hypospadias: 1) Chordee associated with distal hypospadias (skin chordee). This superficial chordee is subcutaneous, proximal to the meatus and can be corrected by mobilization of the skin proximal to the meatus. 2) The other type of chordee is commonly associated with proximal hypospadias. It is usually deep, fibrous and located distal to the meatus. This curvature may be corrected either by Heineke Mikulicz technique, dorsal placcation, corporal rotation or the "Split & Roll technique".

Use of protective intermediate layer (Fig. 11)

The use of an intermediate or interposition layer between the neourethra and the skin layer has greatly improved the results following hypospadias surgery and reduced complications. Types of protective intermediate layer include:

- a) Durham Smith (1973) de-epithelialization
- b) Snow (1986) described the use of Tunica vaginalis wrap.
- c) Retik (1988) was the first to use dorsal subcutaneous flap from the prepuce.
- d) Motiwala (1993) described the use of Dartos flap from the scrotum.
- e) Yamataka (1998) reported the use of external spermatic fascia flap.

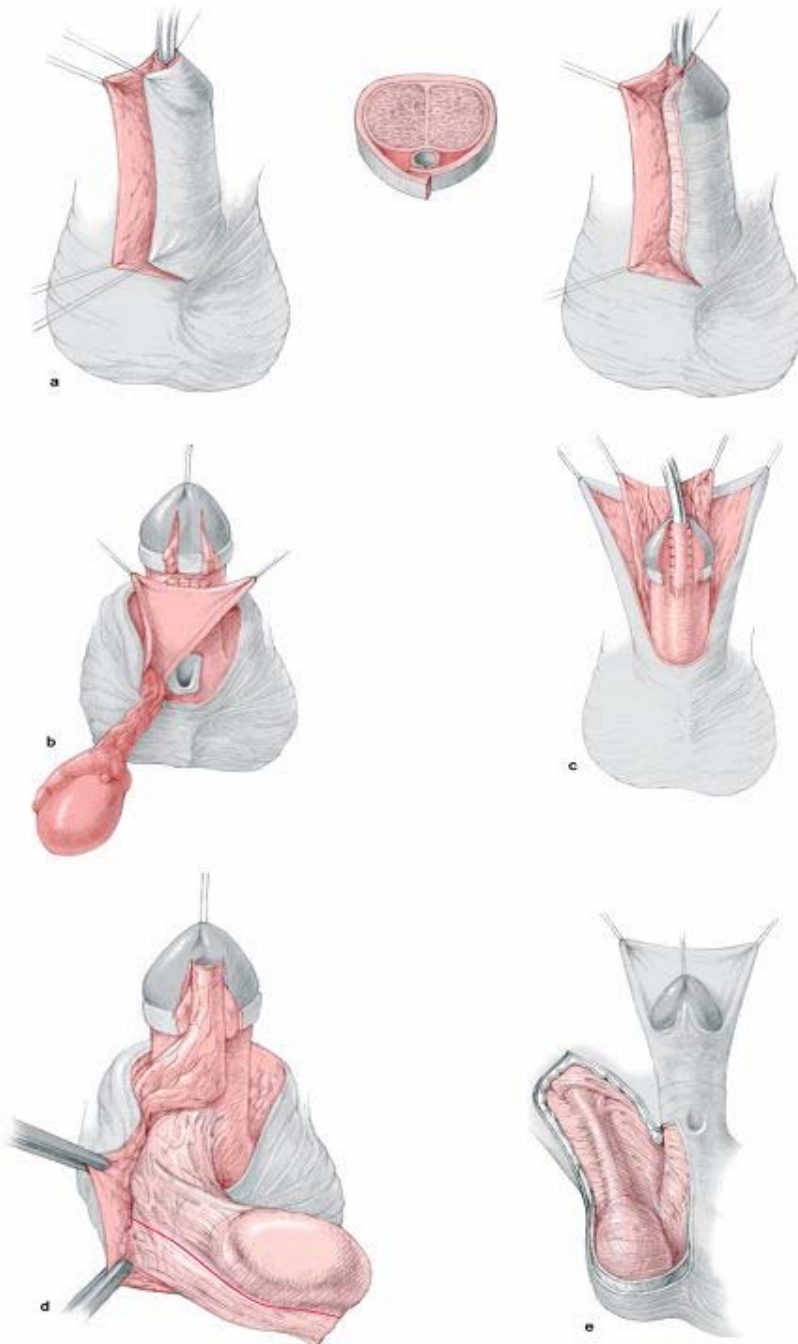


Fig. 11: Methods for protective intermediate layer

Some technical points

- 1) Stenting: several studies showed that stenting of the neourethra may be associated with more complications.
- 2) Dressing: several studies also showed that the type of dressing has a major impact on the outcome of surgery, some studies showed better results without any dressing at all.
- 3) In general, if a complication occurs, one should not operate again before 6 months to allow time for complete healing of the tissues and to give better chance for the success of surgery.
- 4) Fistula management: The most important two steps in the management of fistula are to exclude distal obstruction and to excise the cornu of the fistula to reduce the chances of recurrence.
- 5) Failed distal hypospadias repair: the technique to be adopted depends on the degree of fibrosis and the amount of healthy tissue available. Failed Mathieu repair does not necessarily mean that we can not do another Mathieu repair.
- 6) Failed proximal hypospadias: the most important step is to excise all the unhealthy tissues. Then, according to the healthy tissues available, one may use lateral based flap, a graft ... etc.
- 7) If scrotal transposition is present, it is suggested to correct hypospadias first and then correct the scrotal transposition at a later stage to ensure adequate blood supply to the flap used in urethroplasty.
- 8) The role of tissue culture and tissue engineering is a point of major research. So far the indications for tissue culture in the field of hypospadias are still limited.

Recommended Reading

Hadidi A, Azmy A (eds.) "Hypospadias Surgery, An illustrated guide" (2004), Springer Verlag, Heidelberg, Germany.

<http://www.springer.com/sgw/cda/frontpage/0,11855,1-40109-22-2222375-0,00.html>

All illustrations and operative descriptions are from the book: "Hypospadias surgery, An illustrated guide", Hadidi A, Azmy A (eds.). All rights are reserved for Springer Verlag, Heidelberg, Germany

© by Ahmed Hadidi, 2006